

## Veterinary Use of Radiopharmaceuticals

Jae Cheong Lim\*, So Young Lee, Eun Ha Cho, Sung Soo Nam

Radioisotope Application Research Division, Korea Atomic Energy Research Institute (KAERI), 989-111 Daedeok-daero, Yuseong-gu, Daejeon, 34039, The Republic of Korea

\*Corresponding author: limjc@kaeri.re.kr

### 1. Introduction

Korea has entered the age of 10 million pets, and pets are raised in 1 household per 4 households. The pet industry is constantly growing and in particular, the domestic veterinary drug market is growing at an annual average rate of 7.2% in 2018, amounting to 606 million dollars. In addition, China's veterinary drug market is growing rapidly at an annual rate of 26%, and it is emerging as a promising export market.

In markets of the US and Europe where the pet and veterinary drug industries have matured, SPECT image diagnosis technology is used to diagnose animal's thyroid disease, bone disease, liver disease and kidney disease. PET imaging technology is also used to diagnose cancer in pets. In the field of treatment, I-131 is actively used to treat thyroid disease in cats.

Recently, there is a movement in Korea to utilize radiopharmaceuticals for pets. Therefore, it is expected that the field of application of radiation technology will be expanded to the pet industry.

### 2. Methods and Results

#### 2.1 Treatments of Feline Hyperthyroidism

Hyperthyroidism is a common endocrine disorder in middle-aged and older cats, and they have a functional thyroid adenoma or adenomatous hyperplasia. Typical clinical signs are weight loss, vomiting, diarrhea and several behavioral changes. Anti-thyroid drugs which decrease thyroxine levels can alleviate clinical signs, but do not stop the progression of the disorder. Surgical removal of the thyroid is effective, but there can be many side effects such as hypothyroidism. Therefore, radioactive iodine (Iodine 131, I-131) therapy has been recommended as the first choice for the treatment of feline hyperthyroidism. Anesthesia is not necessary and side effects are rare. Success rates are up to 92% by a single treatment<sup>1,2</sup>.

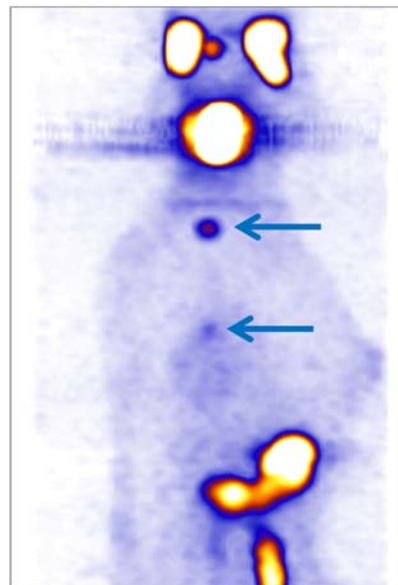


Fig 1. SPECT image acquired after I-131 treatment. There is an intense area of uptake in the cervical region from a thyroid carcinoma with 2 focal areas of less intense uptake (arrows) due to metastases in the thorax<sup>2</sup>

#### 2.2 Bone Scintigraphy of Horses

Scintigraphy in horses offers unique information about the physiological status, and <sup>99m</sup>Tc-MDP (methylene diphosphonate) is used commonly. It can be used in the diagnosis of the most lameness including stress fractures in legs, and the major advantage is an accurate imaging of the upper limbs, pelvis, and vertebral column without general anaesthesia<sup>3</sup>.

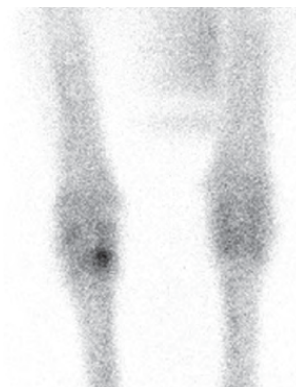

Fig 2. Increased radiopharmaceutical uptake in the right third carpal bone<sup>3</sup>

### 2.3 PET Imaging in Canine Cancer Patients

PET/computed tomography (PET) is used in veterinary medicine to diagnose and stage cancer patients. The most commonly used PET tracer is the glucose analogue 2-deoxy-2-[18F]Fluoro-D-glucose (18F-FDG), and it is good at detecting areas of increased glucose metabolism and can detect primary tumors or metastatic lesion<sup>4</sup>. Veterinary applications of 18F-FDG in oncology are growing with pet owner's growing requests for equivalent care to humans.

[5] A. K. Leblanc, K. Peremans, PET and SPECT Imaging in Veterinary Medicine, *Semin Nucl Med*, 2014;44:47-56

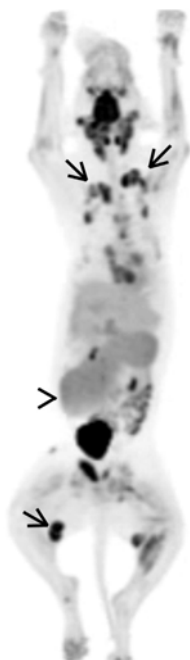


Fig 3. PET imaging of a dog with lymphomas<sup>5</sup>

### 3. Conclusions

Animal treatment with radiopharmaceuticals was used safely for a long time. In Korea, the introduction of radiopharmaceuticals for animals has begun, and interest in development is increasing. Considering the global growth trend of the animal drug market, it is necessary to develop and use new radiopharmaceuticals for animals in Korea.

### REFERENCES

- [1] H. C. Carney, C. R. Ward, S. J. Bailey, D. Bruyette, S. Dennis, D. Ferguson, A. Hinc, A. R. Rucinsky, 2016 AAFP Guidelines for the Management of Feline Hyperthyroidism, *Journal of Feline Medicine and Surgery*, 2016;18:400–416
- [2] M. R. Slater, A. Komkov, L. E. Robinson, D. Hightower, Long-term follow-up of hyperthyroid cats treated with iodine-131, *Veterinary Radiology & Ultrasound*, 1994;3:204-209
- [3] M. Krzemiński, P. Lass, J. Teodorczyk, J. Krajka, Veterinary nuclear medicine, *Nuclear Medicine Review*, 2004;7:177–182
- [4] E. K. Randall, PET-Computed Tomography in Veterinary Medicine, *Vet Clin Small Anim*, 2016;46:515-53